

Bilateral serous retinal detachments from acute hypertensive retinopathy

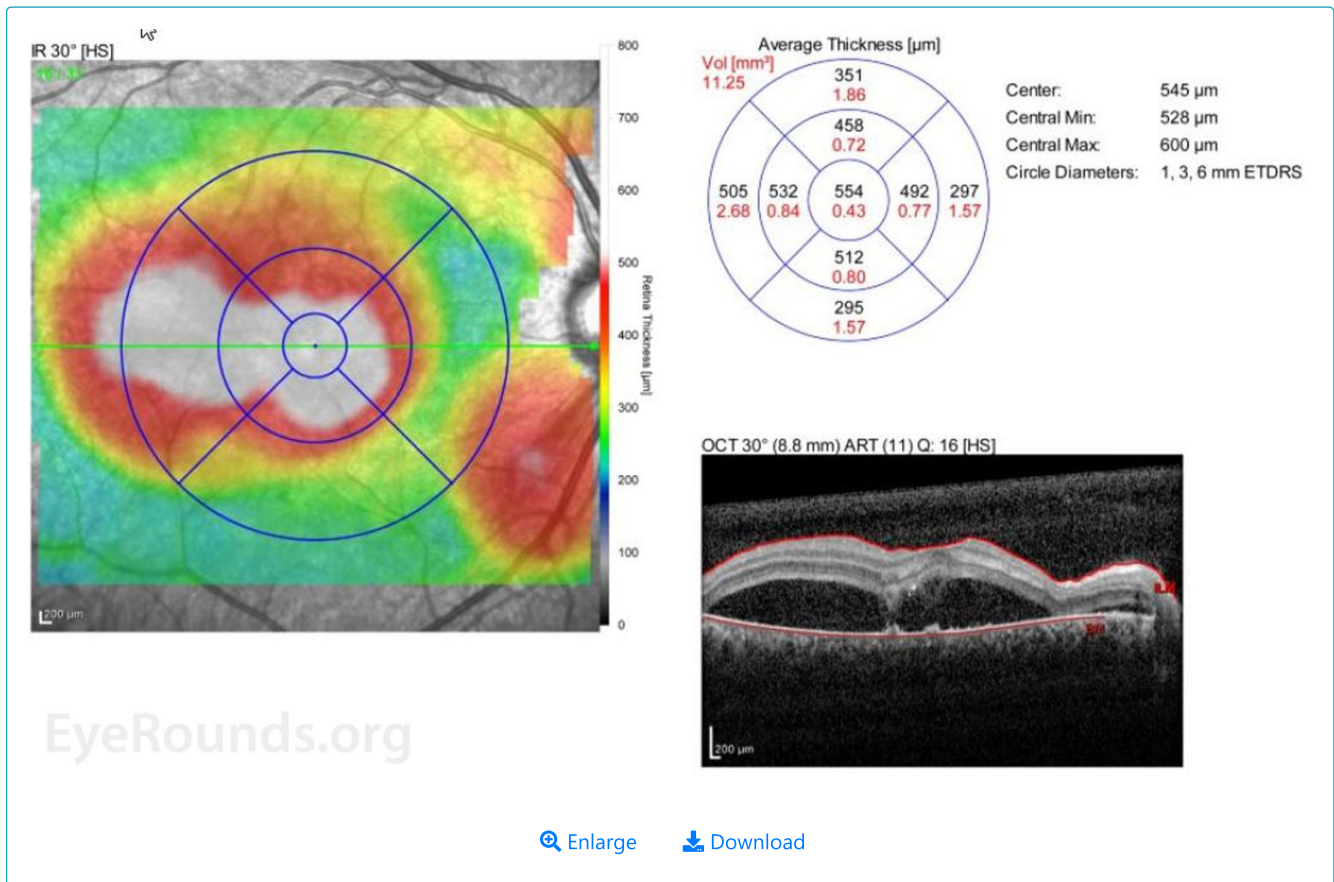
Category(ies): Retina

Contributor: [Ben J. Janson, MD](#)

Photographer: Jody Troyer, CRA

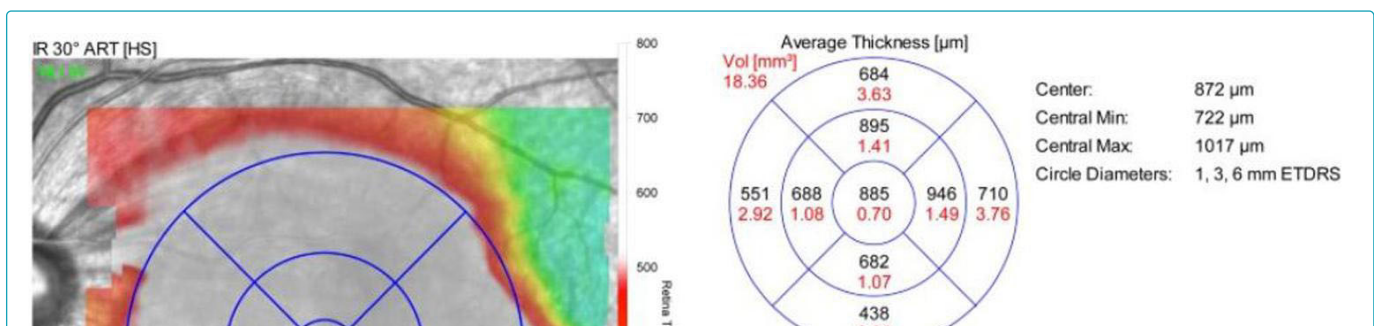
Posted: May 1, 2018

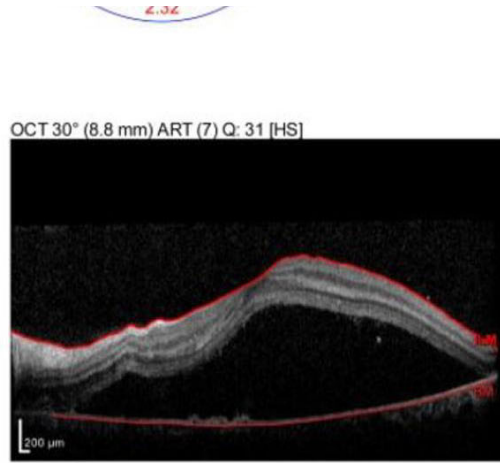
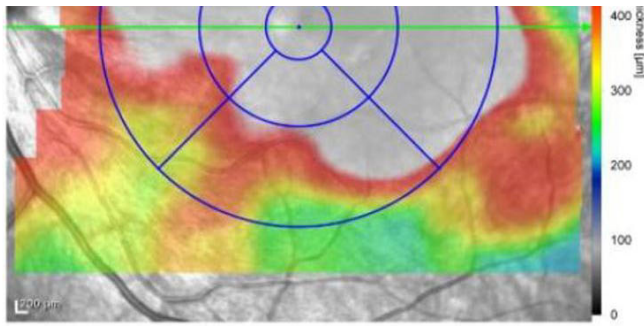
The patient presented with acute onset of blurry vision in both eyes associated with blood pressures exceeding 190/140 mmHg. On dilated exam, both eyes had a flame hemorrhage along the vascular arcade and shifting subretinal fluid in the macula. Acute systemic hypertension more commonly manifests as flame shaped hemorrhages in the nerve fiber layer, but serous retinal detachments have also been reported.[1,2]



EyeRounds.org

Enlarge Download





EyeRounds.org

[Enlarge](#)

[Download](#)

References:

1. Wolfensberger TJ, Tufail A. Systemic disorders associated with detachment of the neurosensory retina and retinal pigment epithelium. *Curr Opin Ophthalmol* 2000; 11(6): 455-61.
2. Systemic arterial hypertension. In: Basic and clinical science course (BCSC) Section 12: Retina and vitreous. Chapter 6 Retinal vascular diseases associated with cardiovascular disease. San Francisco, CA: American Academy of Ophthalmology. 2016-2017.

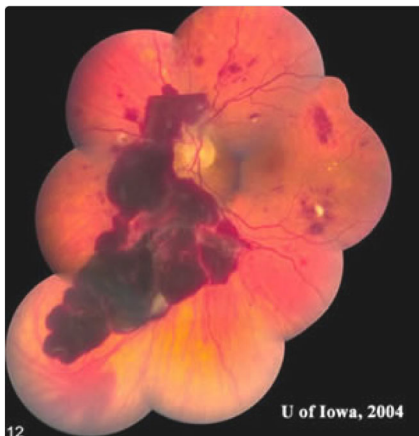Image Permissions:



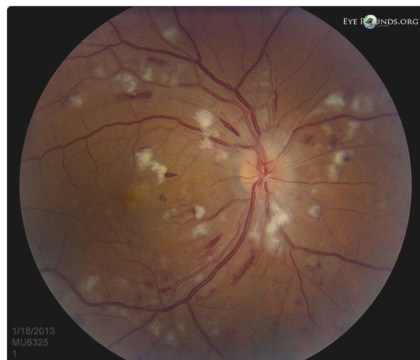Ophthalmic Atlas Images by EyeRounds.org, The University of Iowa are licensed under a [Creative Commons Attribution-NonCommercial-NoDerivs 3.0 Unported License](http://creativecommons.org/licenses/by-nc-nd/3.0/).



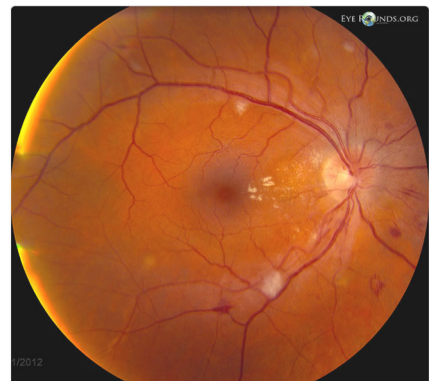Related Articles



12
U of Iowa, 2004
[Related Case: Accelerated Hypertension](#)



[Related Atlas Entry: Malignant Hypertension](#)



[Related Case: Hypertensive retinopathy](#)

Address

University of Iowa
Roy J. and Lucille A. Carver College
of Medicine
Department of Ophthalmology and
Visual Sciences
200 Hawkins Drive
Iowa City, IA 52242

[Support Us](#)

Legal

Copyright © 2019 The University of
Iowa. All Rights Reserved
[Report an issue with this page](#)
[Web Privacy Policy](#) |
[Nondiscrimination Statement](#)

Related Links

[Cataract Surgery for Greenhorns](#)
[EyeTransillumination](#)
[Gonioscopy.org](#)
[Iowa Glaucoma Curriculum](#)
[Iowa Wet Lab](#)
[Patient Information](#)
[Stone Rounds](#)
[The Best Hits Bookshelf](#)

EyeRounds Social Media

Follow



[Receive notification of new cases,
sign up here](#)
[Contact Us](#)
[Submit a Suggestion](#)